

## Liver cirrhosis with chylous hydrothorax and ascites: a case report and literature review

Zhengwei Leng<sup>1\*</sup>, Zhao Yang<sup>2\*</sup>, Songlin Hou<sup>2</sup>, Xiaoqiong Li<sup>2</sup>, Yunfeng Xiao<sup>2</sup>, Sisi Wang<sup>2</sup>, Lu Yang<sup>2</sup>, Guansheng Huang<sup>2</sup>, Jiali Li<sup>2</sup>, Jinrong Xia<sup>2</sup>, Zhengru Chen<sup>2</sup>, Siyu Li<sup>2</sup>, Zhonghui Zhou<sup>2</sup>, Jinghuang Chen<sup>1</sup>, Xia qinghua<sup>1\*</sup>, Tao kaixiong<sup>1\*</sup>

<sup>1</sup>Department of General Surgery, Union Hospital, Huazhong University of Science and Technology. Wuhan, 430022, China

<sup>2</sup>Department of Infectious disease, Affiliated Hospital of North Sichuan Medical College. Nanchong, 637007, China.

**Abstract:** To study the clinical manifestations, pathogenesis, and treatment of liver cirrhosis with chylous hydrothorax and ascites. **Methods:** A case of liver cirrhosis with chylous hydrothorax and ascites was reported and the related literature was reviewed. **Results:** The patient was hospitalized due to massive ascites. Paracentesis and a low-fat diet were effective. Diuretics, liver protection-therapy, and somatostatin were performed. Twenty-eight days later, the patient was asymptomatic without recurrent disease at follow-up three months on. **Conclusions:** Liver cirrhosis with chylous hydrothorax and ascites is rare in clinic patients who have been diagnosed with liver cirrhosis with chylous hydrothorax and ascites exhibits rapid progression and poor prognosis. Low fat and high protein diet should be considered. Diuresis, liver protection-therapy, and the use of somatostatin were performed. The surgery should be performed if necessary.

**Keywords:** Liver cirrhosis; Chylous ascites; Treatment

Received 23 April 2017, Revised 25 May 2017, Accepted 27 May 2017

\*Corresponding Author: Xia qinghua, xiaqinghua@medmail.com.cn; Tao kaixiong, tao\_kaixiong@163.com.

### 1. Introduction

Chylous effusion is rare in clinics, its main characteristic is hydrops in pleural and peritoneal [1]. The cause of the chylous effusion is lymphorrhagia via the lymphatic system obstruction or destroyed, usually, it results in malnutrition and immunodeficiency [2]. Liver cirrhosis with chylous hydrothorax and ascites is rarer still, increases lymph in the liver and gastrointestinal tract because of portal hypertension, which indicates a poor prognosis. Paracentesis, a low-fat and high-protein medium chain triglyceride diet, the diuretics, liver protection-therapy, and somatostatin were effectively performed to reduce the lymph [3]. We reported a patient who presented with chronic alcoholic cirrhosis and his effusion changed into chylous effusion in pleural and peritoneal.

### 2. Case report

A 51-year-old man who was a chronic alcoholic was referred to our hospital on 02-13-2016, because of abdominal distension repeated. He drank white spirit 500ml/day for more than 20 years.

Ascitic fluid test: appearance: milky (Figure 1); Proteins (g/dl): 10.5; Albumin (g/dl): 4.6; Serum—ascites albumin gradient (g/dl): 31; Coagulation: absent; White cells/mm<sup>3</sup>:136; Neutrophils/mm<sup>3</sup>:98; Triglycerides (mg/dl): 2.95; Ascitic fluid culture: absent; Ascites pathology: leukomonocyte, macrophage, no cancer cell.

Abdominal ultrasonography: liver cirrhosis, portal hypertension, a great quantity ascites. Sudan III dye: positive.

Diagnosis: alcoholic cirrhosis, chylous effusion. We treated him with therapies like paracentesis, a low-fat diet, diuretics, antibiotics and so on. The chylous effusion decreased and turned into clear.

He went to the hospital again because of the abdominal swelling. He was discharged after 20 days. Ascitic fluid test: appearance: milky; Proteins (g/dl): 11.0; Albumin (g/dl):4.9; Serum—ascites albumin gradient (g/dl): 35; Coagulation: absent; White cells/mm<sup>3</sup>: 258; Neutrophils/mm<sup>3</sup>: 165; Triglycerides (mg/dl): 2.86. Ascitic fluid culture: absent. Sudan III dye: positive (Figure 2).

At this time, his chylous effusion turned clear in 7 days after he was given octreotide. 28 days later he was discharged.

### 3. Discussion

The disordered lymphatic system reflux and the cisterna chyli branches injured surgically may cause the chylous hydrothorax and ascites in the clinic [4]. Chylous ascites caused by liver cirrhosis may be due to portal hypertension, liver and increased gastrointestinal tract lymph flow [4]. The liver regenerative nodule oppression of thoracic duct caused by lymphatic flow blocked. Thoracic duct drainage could not load the increase in the lymphatic pressure, resulting in lymph circulation disorder, lymph tube leakage or rupture and lymph leakage to

the abdominal cavity and formation of chylous ascites [2].

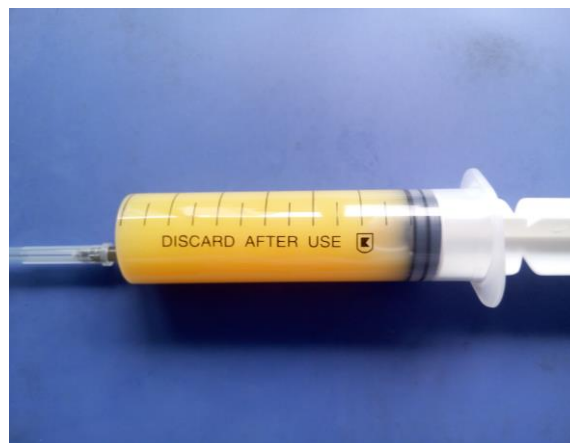Chylous ascites is milky white, Sudan III staining positive, fat globules can be found under the microscope, the content of triglyceride in the ascites >200 mg/dl can be diagnosed [5]. At the same time, imaging examination, such as CT scan, lymphatic imaging will be helpful for diagnosis [5].

Due to a lack of a limited clinical data on chylous ascites, the treatment of chylous ascites is still a big problem. Treatment principle worldwide mainly includes [6]: treating the primary disease actively, limiting sodium intake, limiting water, diuresis, paracentesis, low fat, high protein triglycerides in the diet (total parenteral nutrition when necessary), somatostatin, etc. The purpose of treatment is to improve patients' nutritional status, reduce lymph formation, promote healing of chyle fistula nature [7,8]. The low fat, high protein triglycerides diet can reduce the generation of lymph directly hence reducing the pressure of lymphatic drainage, so as to promote the healing of lymphatic vessels. This can then be directly absorbed by the small intestine, then go to the liver in the form of free fatty acids and glycerol via portal vein [8]. Therefore, the management of the primary disease and a reasonable diet (low fat, high protein-chain triglycerides diet) could be the base and key of treatment [9,10]. Peptide somatostatin and its analogs (octreotide) can bind the gastrointestinal vascular and lymphatic somatostatin receptors to promote lymphatic healing by shrinking the blood vessels and lymphatic vessels, reducing the organ perfusion and portal venous pressure, thus can reduce the lymph formation [11]. We treated the patients by protecting the liver, diuresis, limiting sodium intake, correcting hypoalbuminemia, etc. to manage the underlying disorders; Paracentesis and analgesia were used to alleviate the patient's distension and pain in abdominal. Low fat, high protein triglycerides diet directly reduced lymph production, at the same time, can guarantee the patient's recommended nutritional requirements. Octreotide can also reduce the production of lymph when the intravenous pump is 0.03mg /h last for 4 days, then suspended for 2 days [3]. With the above process ascites gradually turn clear after 7 days treatment. Ascites was significantly reduced after treatment for 28 days then patients were hospital discharge.

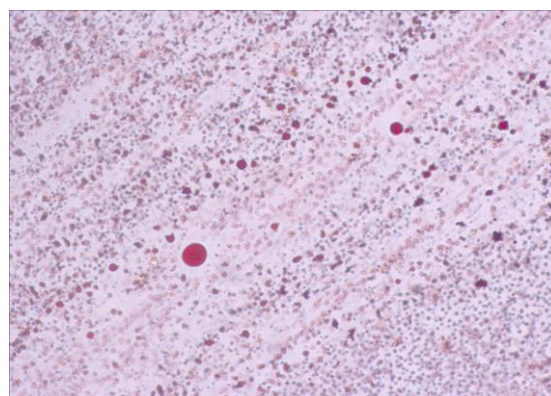
Surgical intervention, including ligating the lymphatic vessels, abdominal jugular vein bypass back, the great saphenous vein bypass surgery, ligating or repairing the lymphatic leaks by laparoscopy, or liver transplantation, usually used when conservative treatment failed. However, more than 50% failure happened in lymphatic ligation. All sorts of bypass surgery can cause sepsis, hypokalemia, diffuse intravascular coagulation, etc.

Ligating the thoracic duct may increase the chylous ascites when patients with chylous hydrothorax and ascites caused by liver cirrhosis [1,12]. Conservative treatment needs more attention because of the many branches, the complicated structure of the lymphatics and the postoperative complications.

Many studies have shown that the formation of chylous ascites after portal hypertension caused by liver cirrhosis indicates the disease progress rapidly with a poor prognosis [1,2]. We managed the disease effectively with the low fat, a high protein triglycerides diet, partial parenteral nutrition, abdominal puncture, drainage, symptomatic treatment, combined with diuresis, protecting the liver, and the octreotide. The treatment is effective and safe, it is worth using for reference in a clinic.



**Figure 1: appearance of ascitic fluid: milky.**



**Figure 2: Sudan III dye: positive.**

## Acknowledgement

This study was supported by National Natural Science Foundation of China (No. 81402444 to Z. Leng), the Key Project of Education Department in Sichuan (No.16ZA0226 to Z. Leng), and the Health and Family Planning Commission of Sichuan Province (No.16PJ133 to Z. Leng ). There is no conflict of interest.

## Referance

- [1] Archimandritis A J, Zonios D I, Karadima D, et al. Gross chylous ascites in cirrhosis with massive portal vein thrombosis: diagnostic value of lymphoscintigraphy. A case report and review of the literature[J]. *European Journal of Gastroenterology & Hepatology*, 2003, 15(1):81-85.
- [2] Wang X R, Review of domestic literature from the 247 patients with chylous ascites[J]. *Journal of clinical digestive diseases*, 2009, 21(1):41-43.
- [3] Yildirim A E, Altun R, Can S, et al. Idiopathic chylous ascites treated with total parenteral nutrition and octreotide. A case report and review of the literature[J]. *Eur J Gastroenterol Hepatol*, 2011, 23(10):961-963.
- [4] Gidaagaya S, Hu J T, Chen D S, et al. Acute rhabdomyolysis and chylous ascites in a patient with cirrhosis and malignant hepatic tumor[J]. *J Formos Med Assoc*, 2014, 113(2):137-138.
- [5] Rector W G. Spontaneous chylous ascites of cirrhosis[J]. *Journal of Clinical Gastroenterology*, 1984, 6(4):369-372.
- [6] Shibuya Y, Asano K, Hayasaka A, et al. A novel therapeutic strategy for chylous ascites after gynecological cancer surgery: a continuous low-pressure drainage system[J]. *Arch Gynecol Obstet*, 2013, 287(5):1005-1008.
- [7] Press O W, Press N O, Kaufman S D. Evaluation and management of chylous ascites[J]. *Ann Intern Med*, 1982, 96(3):358-364.
- [8] Andraus W, Nacif L S, Araujo R L, et al. Chronic pancreatitis associated with chylous ascites simulating liver cirrhosis[J]. *Case Rep Surg*, 2013, 2013:763561.
- [9] Nguyen V, Vassaur H, Buckley F R. Spontaneous chylous ascites, chylomediastinum and bilateral chylothoraces encountered during laparoscopic incarcerated paraesophageal hernia repair[J]. *J Surg Case Rep*, 2015, 2015(10).
- [10] Alam S E, Kar S M, Kar P M. Successful management of chylous ascites: A report of two cases[J]. *Saudi J Kidney Dis Transpl*, 2016, 27(2):386-390.
- [11] Shaked Y, Shpilberg O, Samra Y. Spontaneous chylous ascites in liver cirrhosis[J]. *Harefuah*, 1988, 115(10):277-278.
- [12] Lefrou L, D Alteroche L, Harchaoui Y, et al. Peritoneovenous shunt after failure of octreotide treatment for chylous ascites in lymphangioliomyomatosis[J]. *Digestive diseases and sciences*, 2007, 52(11):3188-3190.